



# Epidermolytic Hyperkeratosis Type I with a New Heterozygous Mutation in *KRT1* Gene: A Case Report

Waqas S. Abdulwahhab<sup>✉,1,2,\*</sup>  Maitha Abdulla Aljuwaied<sup>✉,3</sup>  Moza Kamil Bin Kamil Alshamsi<sup>✉,3</sup>   
Mays Alrim Mustafa Al Moukdad<sup>✉,3</sup>  Sham Zain AlAbdin<sup>✉,4</sup>  Ahmed Elbarkouky<sup>✉,5</sup>   
Omar El Khatib<sup>✉,4</sup>  Salahdein Aburuz<sup>✉,4</sup> 

<sup>1</sup> Consultant Dermatology & Venereology, Department of Dermatology and Venereology, Al Qassimi Hospital, Sharjah, United Arab Emirates

<sup>2</sup> Associate Professor, College of Medicine, Sharjah University, Sharjah, United Arab Emirates

<sup>3</sup> Department of Dermatology and Venereology, Al Qassimi Hospital, Sharjah, United Arab Emirates

<sup>4</sup> Pharmacology and Therapeutic Department, College of Medicine and Health Sciences, United Arab Emirates University, Al Ain, United Arab Emirates

<sup>5</sup> Professor & Consultant Anatomical Pathology, Tanta University Egypt, Purelab, Al Qassimi Hospital, Sharjah, United Arab Emirates

## Article History

Submitted: July 27, 2024

Accepted: October 23, 2024

Published: November 29, 2024

## Abstract

**Background:** Epidermolytic hyperkeratosis (EHK) formerly known as bullous ichthyosiform erythroderma, is a rare autosomal dominant inheritance condition with a prevalence ranging from 1:200,000 to 1:300,000. The underlying etiology of which is a mutation in the genes responsible for keratin proteins synthesis, primarily in *KRT1* and *KRT10* genes, cataloged under OMIM number 113800. The clinicopathological presentations include blistering during the neonatal period, followed by ichthyotic hyperkeratosis in childhood and adolescence. This is characterized by hallmark features such as generalized dry skin, scaling, and hyperkeratosis, and is often associated with erythroderma. EHK may present with or without palmoplantar keratoderma involvement, depending on the keratin gene variant. **Case report:** A 24-year-old male of Arab descent was born with diffuse skin hyperkeratotic plates featuring erythematous fissures, covering his entire body, resembling a collodion baby. His birth was full-term via cesarean section without complications, although he later developed developmental dysplasia of the hip. By the time he started primary school, he began experiencing severe thickening of the skin around his joints, reducing flexibility and leading to contractures and significant disfigurement. He is undergoing treatment with acitretin. Genetic testing using Next-Generation Sequencing (NGS) was performed to identify the responsible gene, revealing a novel heterozygous variant in the *KRT1* gene (OMIM 139350), while no variant was detected in the *KRT10* gene. **Conclusion:** EHK type 1 manifests with a new heterozygous variant in the *KRT1* gene. This rare disorder, associated with variant in genes related to keratin production such as *KRT1* and *KRT10*, results in distinctive skin features present from birth, as well as joint problems and fungal foot infections. Genetic testing has confirmed the presence of a variant in the *KRT1* gene.

## Keywords:

Ichthyosis; Epidermolytic hyperkeratosis; acitretin

## 1. Introduction

Epidermolytic hyperkeratosis (EHK), formerly referred to as bullous congenital ichthyosiform erythroderma, is a rare autosomal dominant skin condition. It is distin-

guished by a significant mutation in the genes responsible for keratin proteins, particularly keratin 1 [*KRT1*] and Keratin 10 [*KRT10*] [1]. Existing literature reports that the prevalence of EHK among infants is approximately 1 in 200,000 infants [1]. Individuals affected by this condi-

\* Corresponding Author:

Waqas S. Abdulwahhab, Department of Dermatology & Venereology, Al Qassimi Hospital, Sharjah, United Arab Emirates; Consultant Dermatology & Venereology, College of Medicine, Sharjah University, Sharjah, United Arab Emirates, wqs\_saad@yahoo.com; Tel.: +00971-508967488



© 2024 Copyright by the Authors.

Licensed as an open access article using a CC BY 4.0 license.

tion will exhibit symptoms such as redness, blisters, and superficial erosions resulting from cytolysis (also known as acanthokeratolysis) at birth. Over the course of a few weeks, the initial presentation of erythroderma and blister formation tends to subside, accompanied by the emergence of hyperkeratosis. This progression reflects the natural evolution of the condition, with changes in the skin's appearance and texture occurring as part of the developmental process [2]. Over time, the erythroderma and blisters gradually improve, although they may persist throughout life. After a few months, verrucous hyperkeratotic plaques become more noticeable in the joints, but can also appear on the scalp, neck, and areas beneath the buttocks. Approximately 60 percent of EHK patients experience involvement of the palms and soles, leading to recurrent painful cracks and contractions that can hinder normal movement [3]. Understanding the clinical features and progression of Epidermolytic hyperkeratosis is crucial for effective diagnosis and management, as well as for providing targeted support to improve the quality of life for affected individuals.

## Case report

A 24-year-old male of Arab descent was born with widespread skin hyperkeratotic plaques with reddened cracks covering his entire body, presenting a collodion baby-like appearance. His birth occurred without complications, albeit he was delivered via cesarean section and later developed hip dysplasia. He was born to parents who are distant cousins, and it is worth noting that there exists no familial history of similar or any dermatological issues among his siblings or other relatives. The patient had widespread erythroderma affecting the full length of his body, followed by hyperkeratosis [Figures 1–3].

Upon starting primary education, he began to experience significant thickening of the skin around his joints due to frequent use during schoolwork and other daily activities. This thickening has led to a reduction in flexibility, limiting the patient's range of motion. The development of contracture in the affected joint led to a progressive and significant disfigurement. The patient's palm displayed severe thickening of the skin and scaly plaques, alongside the presence of yellow-brown lesions due to excessive keratin [Figure 4]. Examination of his feet reveals a pattern of generalized redness, dryness, and skin peeling, with areas of hyperkeratosis causing the formation of yellow and brown patches on the skin. Additionally, notable signs of contracture and toe clawing are evident, indicating a more advanced stage of the condition [Figure 5]. Recent assessments also identified a fungal infection on the patient's foot, which has shown improvement with an-

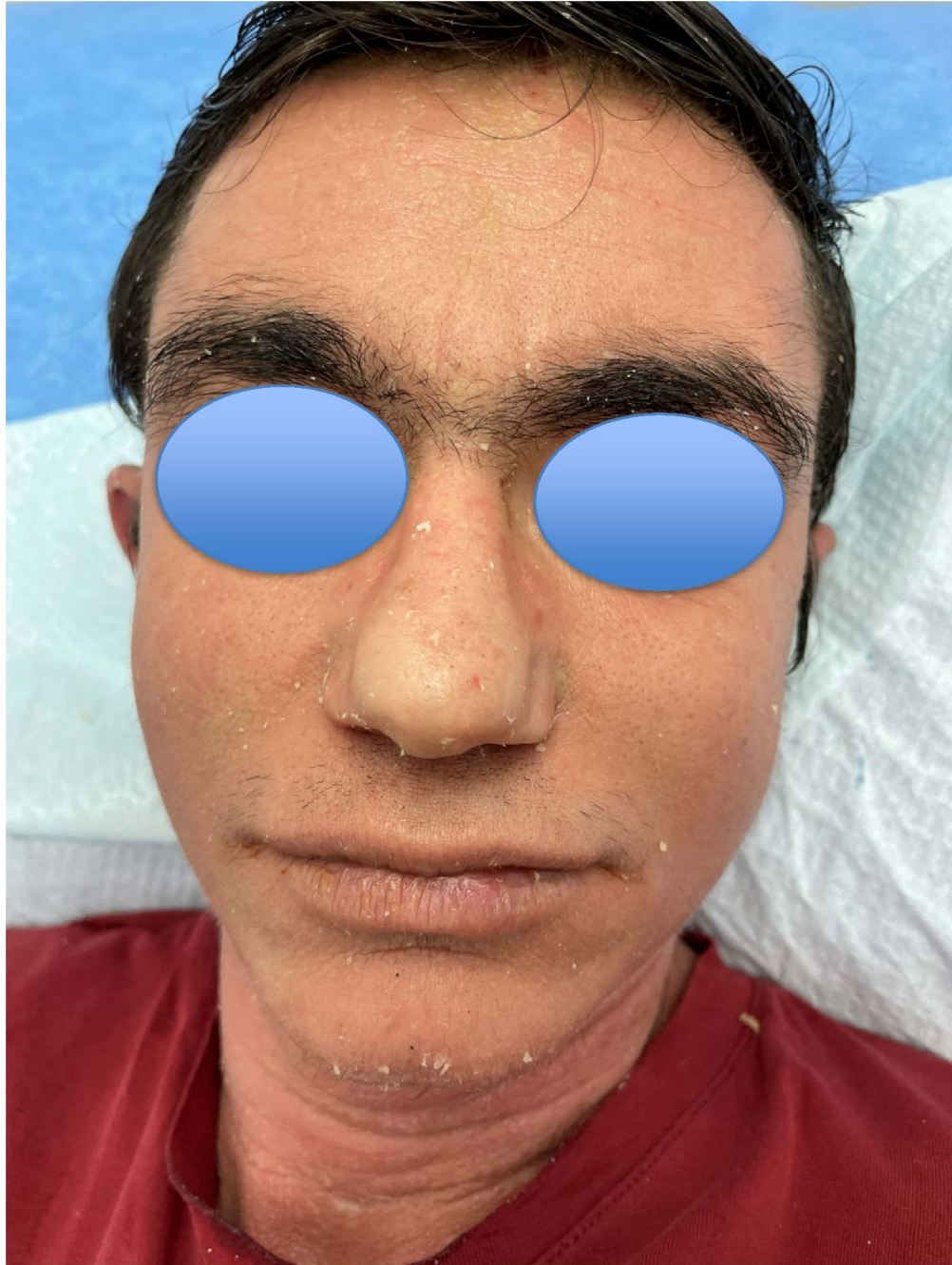tifungal treatment. The histological examination revealed skin tissues that show hyperkeratosis, hypergranulosis, spongiosis, and degenerated vacuolated granular layer. Bulla formation is due to drops of keratocytes (epidermolysis). Genetic testing using Next-Generation Sequencing (NGS) was performed to identify the causative gene. This analysis revealed a novel heterozygous variant in the *KRT1* gene (OMIM 139350) at position c.583A>T, predicting a pathogenic effect [Table 1]. No variant was detected in the *KRT10* gene. The treatment regimen includes acitretin 30 mg capsule, Betamethasone Scalp 0.1% Lotion, celecoxib 200 mg Capsule, coal tar-salicylic acid topical, emollient Creams, white soft paraffin topical cream, and Urea 10% Cream.

## 2. Discussion

EHK represents a notably rare form of ichthyosis that distinctly presents itself clinically at birth. This condition holds specific significance due to its relatively low prevalence, affecting approximately 1 in 300,000 individuals. The defining clinical features of EHK encompass pronounced hyperkeratotic scaliness, marked by severe blistering precipitated by cytolysis within the suprabasal layer, alongside excessive cellular proliferation within the basal layer. Additionally, the histological examination of individuals with EHK reveals distinctive characteristics, including increased thickness of the granular layer and stratum corneum, along with enlarged cells with irregular morphology within epidermal layers [4].

Moreover, EHK is associated with mutations occurring in the highly conserved  $\alpha$ -helical rod domains of keratin 1 and keratin 10. Mutations within helix boundary sequence motifs have a significant impact on the processes of helix initiation and termination, causing significant disruption in filament assembly and tonofilament aggregation. This ultimately leads to the manifestation of more severe phenotypic outcomes [5]. The impaired epidermis is prone to cytolysis and blister formation, disrupting the skin barrier function, and resulting in increased trans epidermal moisture loss and microbial overgrowth. Hyperkeratosis results from increased cell proliferation within the basal layer, along with reduced desquamation [6].

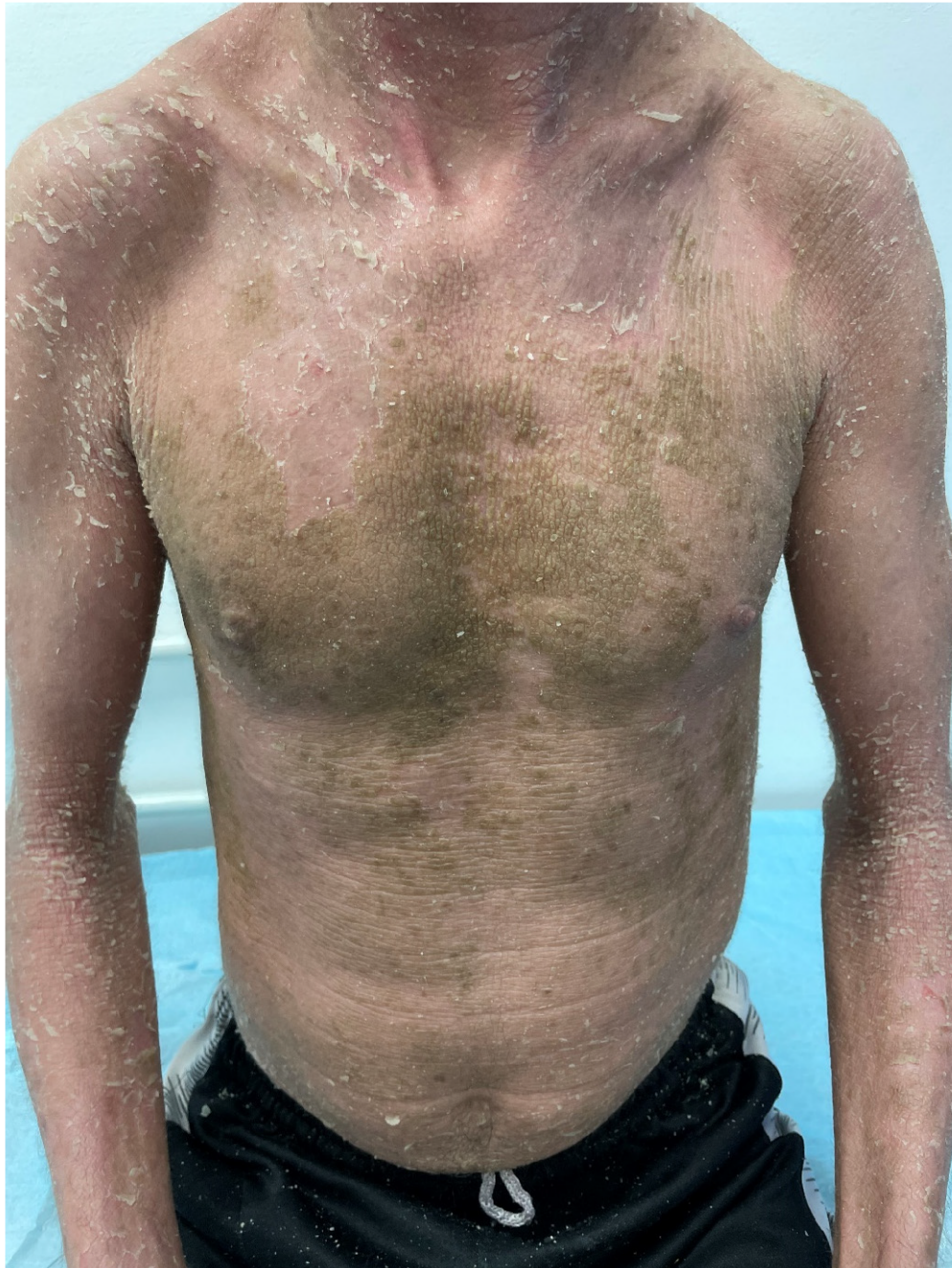EHK is evident at birth, characterized by generalized erythroderma. The fragility of the skin contributes to the development of blisters, peeling or exfoliation, erosions, and significant areas of denuded skin, even in response to minimal trauma. Over the subsequent months, the erythema and blistering decrease, while pronounced hyperkeratosis emerges. In some cases, the fragility of the skin may persist, resulting in the periodic shedding of large segments of the superficial epidermis. In other



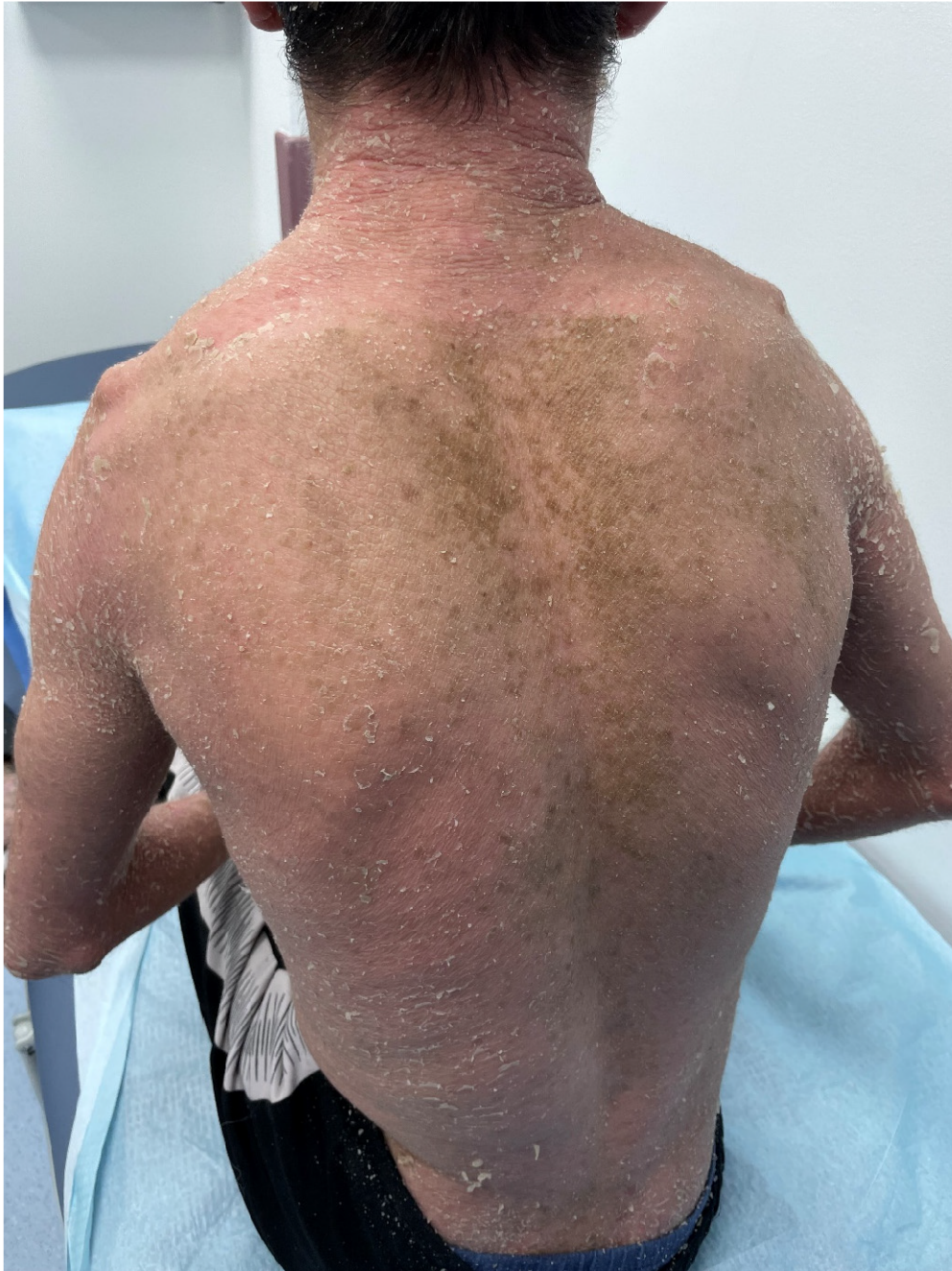**Figure 1:** A 24-year-old male patient with EHK showed widespread Erythroderma of the face.

**Table 1:** Showed Molecular genetic analysis for epidermolytic hyperkeratosis.

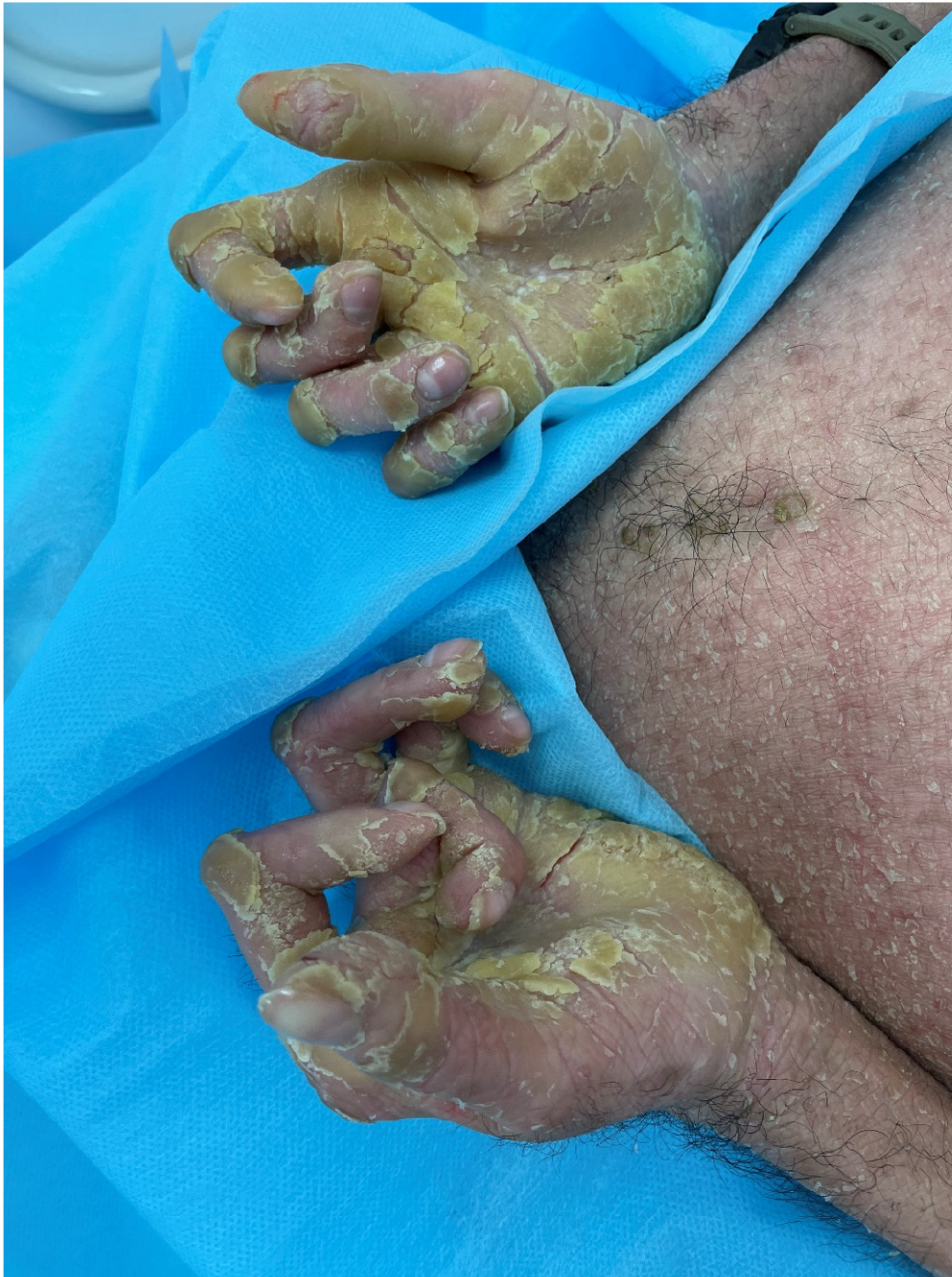Gene (Isoform)	Phenotype MIM Number (Mode of Inheritance)	Variant	Zygosity	MAF GnomAD [%]	Classification
<i>KRT1</i> (NM_006121.4)	600962 (AD) 146590 (AD) 113800 (AD) 620148 (AD) 607654 (AD) 620411 (AD)	c.583A>T p.(Ile195Phe) chr 12:53073550	het.	0	likely pathogenic



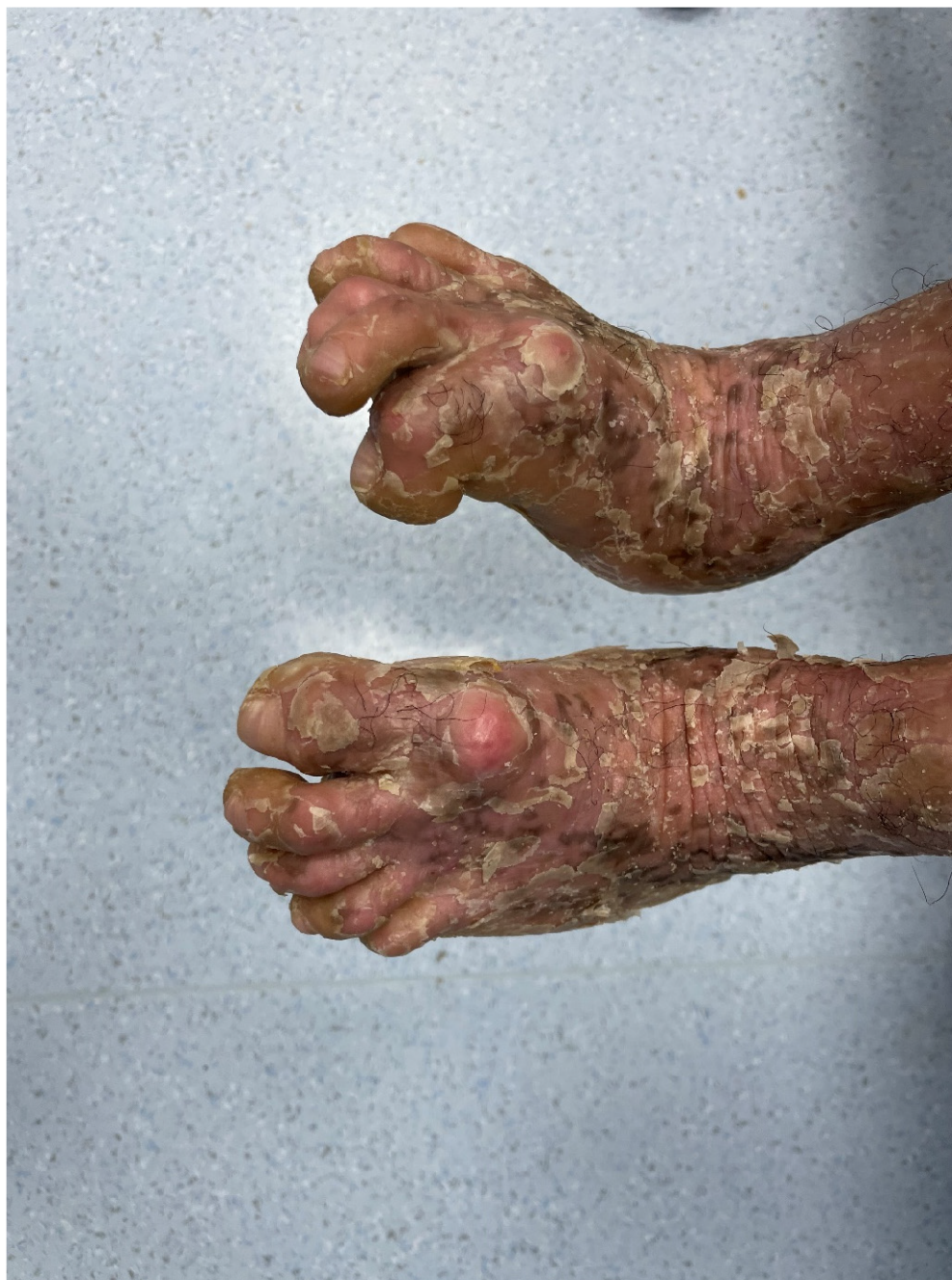**Figure 2:** A 24-year-old male patient with EHK showed widespread erythroderma of trunk and flexures with hyperkeratosis (corrugated cardboard-like) dark-brown dry pattern scales.



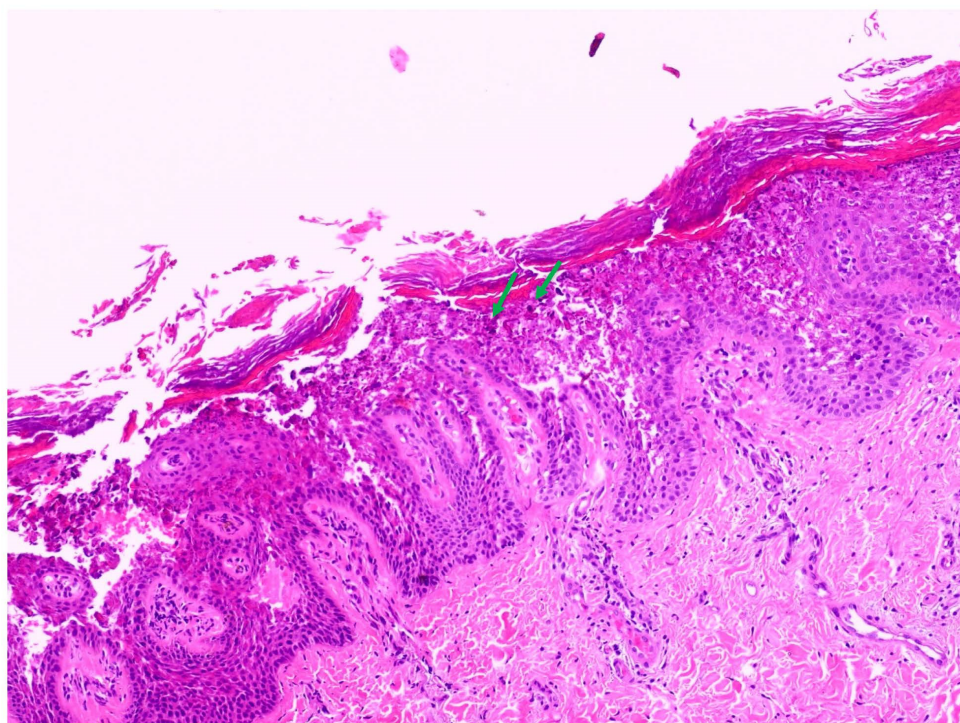
**Figure 3:** A 24-year-old male patient with EHK showed widespread erythroderma of back with hyperkeratosis (corrugated cardboard-like) dark-brown dry pattern scales.



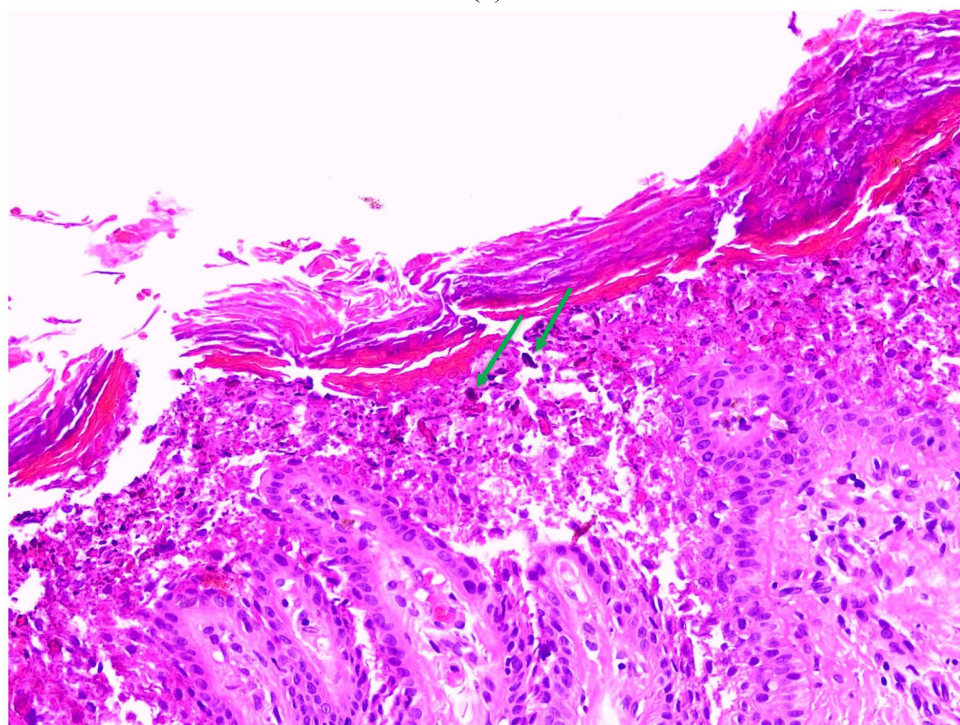
**Figure 4:** A 24-year-old male patient with EHK showed severe thickening, yellowish hyperkeratosis surrounding the hand's joints and significant disfigurement and flexure contracture of fingers.



**Figure 5:** A 24-year-old male patient with EHK showed severe thickening, yellowish hyperkeratosis and significant disfigurement of feet with contractures and toes clawing.



(a)



(b)

**Figure 6:** (a) Hematoxylin & eosin stain section showed hyperkeratosis, hypergranulosis (arrows) with degenerated vacuolated granular layer, and spongiosis. Note bulla formation is due to drops of keratocytes (epidermolysis). X10. (b) Hematoxylin & eosin stain section showed hyperkeratosis, hypergranulosis (arrows) with degenerated vacuolated granular layer, and spongiosis. Note bulla formation is due to drops of keratocytes (epidermolysis). X40.

**Table 2:** Showed differential diagnosis for Epidermolytic Hyperkeratosis (EHK).

Diagnosis	Clinical Findings	Genetic Basis	Key Differentiators
Epidermolytic Hyperkeratosis (EHK)	Hyperkeratosis, erythroderma, blistering, thickened skin with verrucous plaques; symptoms typically present at birth.	Mutations in <i>KRT1</i> or <i>KRT10</i> genes (OMIM 113800).	Autosomal dominant inheritance; early onset; distinctive histological features including epidermal hyperkeratosis.
Ichthyosis Vulgaris	Dry, scaly skin, primarily affecting extensor surfaces; often less severe than EHK.	Mutations in the <i>FLG</i> gene.	More diffuse scaling; onset usually in early childhood; not associated with blistering.
Harlequin Ichthyosis	Severe, thick, plate-like scales covering most of the body; severe at birth.	Mutations in the <i>ABCA12</i> gene.	Extremely severe, life-threatening; associated with a characteristic thickened skin appearance and tight skin.
Bullous Congenital Ichthyosiform Erythroderma	Redness, blistering, and erosions at birth, followed by scaling and thickening.	Mutations in <i>TGM1</i> gene.	Similar early presentation to EHK but different underlying genetic cause; usually resolves somewhat with age.
Lamellar Ichthyosis	Thick, brown, plate-like scales; often more generalized skin involvement; less severe blistering.	Mutations in the <i>TGM1</i> or <i>ABCA12</i> genes.	Scaling tends to be more uniform; associated with a distinct lamellar scale pattern.
Keratinocytic Epidermal Nevus	Localized thickened skin lesions; may present as warty or verrucous plaques.	Not typically associated with a specific genetic mutation.	Lesions are usually localized and not widespread; usually presents later in life.

instances, severe involvement of the scalp and neck is observed, leading to encasement of hair shafts and alopecia. Bacterial colonization of the degraded scales results in a distinctive and foul odor. The literature indicates that commonly associated symptoms include xerosis, pruritus, painful fissuring, anhidrosis, and reduced joint mobility [7,8]. Our patient had widespread erythroderma affecting the full length of his body, followed by hyperkeratosis, thickening of the skin surrounding the joints, and significant disfigurement and hyperkeratosis with flexure contractures of fingers and toes clawing.

Several phenotypic variations of EHK have been identified by investigators. Through their study in 1994, DiGiovanna and Bale outlined two main clinical categories: with palmoplantar keratoderma and without palmoplantar keratoderma [6]. Each category encompasses three subtypes presenting with differing degrees of erythroderma, blistering, scaling (non-palmoplantar type), and truncal involvement (palmoplantar type) [6]. Palmoplantar involvement can result in digital contractures, leading to functional impairment. The case report details the palmoplantar type of ichthyosis, characterized by significant flexure contractures in the fingers and toes, which present as clawing. This suggests a more advanced stage of the condition. The diagnosis of EHK is established based on clinical criteria [9]. However, only one clinical

scoring framework has been proposed so far, which incorporates light-dim scaling, keratosis pilaris, and expanded palmoplantar markings for the diagnosis of EHK. Hyperkeratosis can present with varying severity, often being more pronounced over joints and in flexural regions, with the scales characterized by a corrugated or cardboard-like appearance [10]. Joint contractures may also develop in certain patients. Moreover, hair, nails, and teeth are usually not affected, and ectropion is generally not observed [10]. The prevalence of superficial bacterial infections is notable, often accompanied by a distinctive foul odor of the skin. Key symptoms relevant to prognosis include xerosis, pruritus, painful fissures of the thickened skin, erythema, anhidrosis, ectropion, and limited joint mobility [11].

Examination of the histopathological samples of EHK revealed the presence of orthokeratosis hyperkeratosis, papillomatosis, hypergranulosis, acanthosis, vacuolization of granulosal and Malpighian cells, and keratohyalin granules dispersed in the vacuolated granular layer [12,13].

This condition is attributable to mutations in keratin 1 (*KRT1*) and 10 (*KRT10*), encoded by genes located on chromosomes 12q13.3 and 17q21.2. Keratins constitute a structural network within the cell, providing support and facilitating the three-dimensional organization of ker-

atinocytes. In the basal layer, keratinocytes express keratins 5 and 14, while in the spinous and granular layers, they express keratins 1 and 10. Consequently, mutations in keratins 1 and/or 10 compromise the integrity of keratinocytes within upper layers of the epidermis, leading to the vacuolar appearance characteristic of this condition [14].

In the case report, the analysis of DNA within the *KRT1* gene revealed a specific alteration at position c.583A>T, resulting in the substitution of Isoleucine with Phenylalanine at amino acid position 195 in the corresponding protein [Table 1]. Computational predictions suggest a potential detrimental impact on protein function, albeit lacking mention in current literature [15]. Comparable changes at this gene locus have been documented in individuals with epidermolytic ichthyosis, indicating a plausible association between this genetic variation and skin disorders. This novel genetic finding, observed in a heterozygous state within the patient, has been classified as likely pathogenic due to its association with skin-related mutations linked to epidermolytic hyperkeratosis type 1 (EHK1). In addition to the autosomal dominant inheritance pattern characteristic of Epidermolytic Hyperkeratosis (EHK), it is noteworthy that the patient's parents are distant cousins. This consanguinity could potentially increase the likelihood of inheriting genetic mutations from a common ancestor. Constructing a detailed family genealogy would provide more specific insights into the inheritance dynamics and enhance our understanding of how consanguinity might affect the presentation of EHK in this case. A distinctive heterozygous variant of the *KRT1* gene was identified through genetic analysis, corresponding with the clinical manifestations observed in the patient. This variant likely correlates with the observed skin condition. To further validate the diagnosis and assess the inheritance pattern, parental genetic testing is recommended. If confirmed as the causal factor, this variant implies a 50% chance of inheritance by the patient's offspring. However, disease manifestation may be influenced by factors such as incomplete penetrance and variable expressivity.

There is presently no cure for EHK. Treatment primarily focuses on managing symptoms by considering three key factors: the patient's age, gender, the specific type of disease—whether it manifests as xerotic, scaly, or accompanied by fissures—and finally, assessing the degree and location of skin lesions [11,15]. For xerotic lesions mainly the treatment is based on emollients containing NaCl, glycerol, urea, lipids, petroleum-like alpha-hydroxy acids, and propylene glycol, which aim to hydrate the skin [12]. Thick scaly lesions require keratolytic agents like tazarotene [13], N-acetylcysteine [14],

liarozole, and calcipotriol [15]. However, employing excessively potent keratolytic treatments may exacerbate the condition by further compromising the skin's protective barrier. This can increase the risk of painful blisters and susceptible skin breakdown, leading to potential infections. In instances where patients suffer from fissures, crevices, or erosions, keratolytics are avoided and instead treated with antimicrobials until the affected areas are healed. These antimicrobials typically involve retinoids and calcipotriol. Topical treatments comprise the primary approach for managing hyperkeratosis as genetic therapy remains ineffective [14,15]. In severe cases, oral retinoids are used, exerting a keratolytic effect that helps remove scales from the skin's surface and prevents excessive thickening. This treatment restores a more normal thickness and improves the function of the outer layer, known as the stratum corneum [16]. The differential diagnosis of EHK encompasses various conditions that present with erythroderma, bullae/blisters, or exfoliation: Superficial epidermolytic ichthyosis, Lamellar ichthyosis, Congenital ichthyosiform erythroderma, Pityriasis rubra pilaris; Vesiculobullous and erosive disorders in childhood: Epidermolysis bullosa, Staphylococcal scalded skin syndrome, Bullous impetigo, Herpes simplex, Congenital erosive and vesicular dermatosis, Autoimmune blistering diseases; Genodermatoses: Sjogren-Larsson syndrome, Neutral lipid storage disease, Trichothiodystrophy, Netherton syndrome, Steroid sulfatase deficiency, Peeling skin syndromes, Conradi-Hunermann-Happle syndrome, CHILD syndrome, KID syndrome [17,18].

In this particular report, the patient received treatment using topical emollients and keratolytics. However, substantial progress in skin thickness and increased hand functionality was reported upon the commencement of oral retinoids.

### 3. Conclusions

EHK type 1 manifests with a new heterozygous mutation in the *KRT1* gene confirmed by genetic analysis. This variant has not been reported in the literature to the best of our knowledge. Epidermolytic hyperkeratosis is a rare disorder with a challenging differential diagnosis. Despite this, it is important for clinicians to be able to identify the disease in the earliest stages in order to reduce the risk of morbidity and mortality.

### 4. List of Abbreviations

- EHK: Epidermolytic hyperkeratosis;
- KRT-1: Keratin 1 gene;
- KRT-10: Keratin 10 gene;

- NGS: Next-Generation Sequencing.

## Author Contributions

W.S.A: Conceptualization, Data Curation, Formal Analysis, Investigation, Methodology, Project administration, Resources, Supervision, Validation, and Writing. M.K.B.K.A.: Data Curation, Writing, Review and Editing. M.A.M.A.M.: Data Curation, Writing, Review and Editing. M.A.A: Data Curation, Writing, Review and Editing. S.Z.: Data Curation, Writing, Review and Editing. A.E.: Data Curation, Formal Analysis, Methodology, and Validation. O.E.K.: Data Curation, Writing, Review and Editing. S.A.: Data Curation, Writing, Review and Editing.

## Ethical Consideration

The study has been approved by the research ethics committee of Dubai Research Ethics Committee at Ministry of Health and Prevention (Ref. No.: MOHAP/DXB-REC/J.J.J/No.19/2024).

## Human Rights Statement

The study has been conducted in accordance with the with the ethical standards of the committee responsible for human experimentation (institutional and national), and with the Helsinki Declaration of 1975, as revised in 2013.

## Availability of Data and Materials

The data that support the findings of this study are available on request from the corresponding author. The data are not publicly available due to privacy or ethical restrictions.

## Consent for Publication

Written informed consent has been obtained from the patient to publish this paper.

## Conflict of Interest

The authors declare no conflicts of interest regarding this manuscript.

## Funding

This research received no specific grant from any funding agency in the public, commercial, or not-for-profit sectors.

## References

- [1] Peter Rout, D.; Nair, A.; Gupta, A.; Kumar, P. Epidermolytic hyperkeratosis: Clinical update. *Clin. Cosmet. Investig. Dermatol.* **2019**, *12*, 333–344. [CrossRef] [PubMed]

- [2] Arin, M.J.; Longley, M.A.; Anton-Lamprecht, I.; Kurze, G.; Huber, M.; Hohl, D.; Rothnagel, J.A.; Roop, D.R. A novel substitution in keratin 10 in epidermolytic hyperkeratosis. *J. Investig. Dermatol.* **1999**, *112*, 506–508. [CrossRef] [PubMed]
- [3] Kwak, J.; Maverakis, E. Epidermolytic hyperkeratosis. *Dermatol. Online J.* **2006**, *12*, 6. [CrossRef] [PubMed]
- [4] Fuchs, E.; Esteves, R.A.; Coulombe, P.A. Transgenic mice expressing a mutant keratin 10 gene reveal the likely genetic basis for epidermolytic hyperkeratosis. *Proc. Natl. Acad. Sci. USA* **1992**, *89*, 6906–6910. [CrossRef] [PubMed]
- [5] Irvine, A.D.; McLean, W.H. Human keratin diseases: The increasing spectrum of disease and subtlety of the phenotype-genotype correlation. *Br. J. Dermatol.* **1999**, *140*, 815–828. [CrossRef] [PubMed]
- [6] DiGiovanna, J.J.; Bale, S.J. Epidermolytic hyperkeratosis: applied molecular genetics. *J. Investig. Dermatol.* **1994**, *102*, 390–394. [CrossRef] [PubMed]
- [7] Hayashida, M.T.; Mitsui, G.L.; Reis, N.I.; Fantinato, G.; Jordão Neto, D.; Mercante, A.M. Epidermolytic Hyperkeratosis--case report. *An. Bras. De Dermatol.* **2015**, *90*, 888–891. [CrossRef] [PubMed]
- [8] Mendes, M.S.; Kouzak, S.S.; Aquino, T.A.; Takano, G.H.; Lima, A.d.P. Mosaic epidermolytic ichthyosis--case report. *An. Bras. De Dermatol.* **2013**, *88* (Suppl. 1), 116–119. [CrossRef] [PubMed]
- [9] Congenital Ichthyosis: An Overview of Current and Emerging Therapies. (n.d.). EBSCO. Available online: <https://research-ebSCO-com.uaeu.idm.oclc.org/cqql2cy/viewer/pdf/htkw45pop5> (accessed on 22 May 2024).
- [10] Lessin, S.R.; Huebner, K.; Isobe, M.; Croce, C.M.; Steinert, P.M. Chromosomal mapping of human keratin genes: evidence of non-linkage. *J. Investig. Dermatol.* **1988**, *91*, 572–578. [CrossRef] [PubMed]
- [11] Topical Application of Tazarotene in the Treatment of Nonerythrodermic Lamellar Ichthyosis. (n.d.). *JAMA Dermatol.* Available online: <https://jamanetwork.com/journals/jamadermatology/article-abstract/189028> (accessed on 22 May 2024).
- [12] Redondo, P.; Bauzá, A. Topical N-acetylcysteine for lamellar ichthyosis. *Lancet (Lond. Engl.)* **1999**, *354*, 1880. [CrossRef]
- [13] Sarici, S.U.; Sahin, M.; Yurdakök, M. Topical N-acetylcysteine treatment in neonatal ichthyosis. *Turk. J. Pediatr.* **2003**, *45*, 245–247.
- [14] Bogenrieder, T.; Landthaler, M.; Stolz, W. Bullous congenital ichthyosiform erythroderma: Safe and effective topical treatment with calcipotriol ointment in a child. *Acta Derm.-Venereol.* **2003**, *83*, 52–54. [CrossRef]
- [15] Lucker, G.P.; van de Kerkhof, P.C.; van Dijk, M.R.; Steijlen, P.M. Effect of topical calcipotriol on congenital ichthyoses. *Br. J. Dermatol.* **1994**, *131*, 546–550. [CrossRef] [PubMed]

- [16] DiGiovanna, J.J.; Mauro, T.; Milstone, L.M.; Schmuth, M.; Toro, J. Systemic retinoids in the management of ichthyoses and related skin types. *Dermatol. Ther.* **2013**, *26*, 26–38. [[CrossRef](#)] [[PubMed](#)]
- [17] Rice, A.S.; Crane, J.S. Epidermolytic hyperkeratosis. In *StatPearls [Internet]*; StatPearls Publishing: Treasure Island, FL, USA, 2024. Available online: <http://www.ncbi.nlm.nih.gov/books/NBK544323/> (accessed on 22 May 2024).
- [18] Sharquie, K.; Abdulwahhab, W. Keratoderma of palms and soles is an umbrella for the first manifestation of different skin diseases. *J. Pak. Assoc. Dermatol.* **2023**, *33*, 559–565.